

Supernumerary Breast Tissue: Historical Perspectives and Clinical Features

Norman A. Grossl, MD, Department of Pathology and Laboratory Medicine, Emory University School of Medicine.

Posted: 01/01/2000; South Med J. 2000;93(1) © 2000 Lippincott Williams & Wilkins



Abstract and Introduction

Abstract

The presence of extra nipples and breasts, polythelia and polymastia respectively, is not uncommon. Such supernumerary breast tissue usually is found within the milk line extending from the axilla to pubic region. It was once thought that this condition was a symbol of increased fertility and femininity. Anne Boleyn was said to have a third breast. Ancient goddesses of fertility had row upon row of breasts on their chests. Polythelia is seen congenitally. Ectopic breast tissue and polymastia may not appear until enhanced by sex hormones during puberty or early pregnancy. The same pathology that can affect normally positioned breasts, including carcinoma, can occur in supernumerary breast tissue. Renal and other organ system anomalies are associated with supernumerary breast tissue. Further research is needed to establish the clinical significance of supernumerary breast tissue in light of its reported associated conditions. Appropriate treatment is yet to be refined.

Introduction

Polymastia (supernumerary breasts) and polythelia (supernumerary nipples) are extras in sites unexpected. These anomalies appear more so in women than men. The full spectrum of extra parts -- from nipples to fully formed breasts -- is wide-ranging. Polymastia may be seen as a normally shaped female breast with a nipple and areola. In attenuated forms it may be breast tissue with nipple lacking areola, glandular tissue with areola but without nipple, or only ectopic breast tissue with neither areola nor nipple.^[1] Supernumerary nipples are often miniature compared to normally placed nipples. The occurrence of extra breasts and nipples varies, but it generally is in the range of 1% to 2% of the general population^[2-4] and is reported to be as high as 6%.^[5]

The genesis of extra breasts lies in hidden, quiescent primordial breast tissue along "Hughes lines," also known as mammary lines or simply "milk lines."^[6] In the fourth to fifth weeks of normal embryonic development, two surface thickenings occur along the sides of the embryo extending from the axillary region to the groin. In 2 to 3 months, these thickenings become more pronounced as mammary ridges -- the future site of breasts. Normally most of these ridges (all except two) regress.^[6] But as imperceptibly as the germination of a dormant seed in early spring soil, such ectopic quiet breast rudiments can come to life in the right hormonal milieu. When awash in sex hormones at puberty or during pregnancy, such tissue can blossom (Fig 1). And it is not exempt from the physiology and pathology of normally positioned breasts. A common site of ectopic breast tissue is the axilla. Such an occurrence can cause discomfort after childbearing when it lactates in unison with its two sanctioned colleagues.



Figure 1. Illustration of polymastia and polythelia.

History

Fertility goddesses of the ancients were often well-endowed with multiple breasts. The goddess Artemis of Ephesus^[7(pp 32-34)] had a plethora of breasts arranged in neat rows on her torso (Fig 2). Her cult was preoccupied with fertility and wild orgies. Ironically, Artemis was a virgin. A vestige from Artemis and her Phoenician counterpart cult goddess Astarte^[7(pp 36,37)] is the folklore belief that the presence of multiple breasts is a sign of abundant fertility and femininity.^[8] In 19th-century medical literature a higher incidence of plural births in such women was suggested^[8(p52,53,85)] (a theory currently not supported). Anne Boleyn, the second wife of Henry VIII, was said to be polydactyl and to have a third breast.^[8] She was with child when Henry pleaded with the Pope to grant an official end to his first marriage from Catherine of Aragon. Anne's pregnancy probably had little to do with third breasts, however. She did bear him a daughter, but not the male heir he long desired. Perhaps in time his wish might have been fulfilled if Anne's life were not truncated by decapitation.

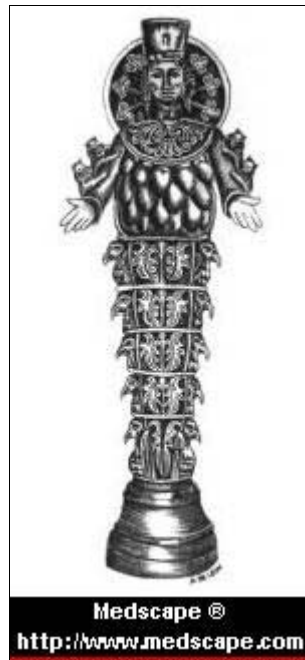


Figure 2. Illustration of goddess Artemis of Ephesus.

Charles Darwin^[9] reflected on polymastia in humans and concluded it was an evolutionary throwback. He believed that milestones of embryologic development recapitulate human evolution. The embryo at one point resembles a fish, then a reptile, and so on until it becomes a recognizable human form. More primitive mammals beneath humans on the evolutionary scale have multiple breasts arranged along milk lines. When such a primitive reversion manifested itself in women, Darwin saw a proof of evolution in this atavistic fingerprint. In this view, multiple breasts and nipples are considered obsolete parts, such as wisdom teeth and the appendix. Although this was an interesting explanation for polymastia, it did not explain all cases, especially those occurring outside the milk line.

Clinical Features

As mentioned, ectopic breast tissue can undergo the same pathologic changes as normal breasts. Cases of ectopic breast with benign cystic changes,^[10] benign tumors (adenomas and fibroadenomas),^[11,12] and carcinoma are documented.^[13] When a mass is located along the milk line, the possibility of the presence of breast tissue should be considered. Such masses, for instance in the axilla, may on initial inspection be mistaken for an enlarged lymph node. A handful of cases of breast carcinoma arising in ectopic vulvar breast tissue have been reported.^[14] Such cases can present a challenge for both the clinician and the pathologist in making the correct diagnosis. Supernumerary breasts and nipples for the most part present only a cosmetic problem and may be surgically removed. They also may be removed when causing discomfort due to tenderness or when secreting milk. In cases of carcinoma, wide surgical excisions are recommended, with appropriate follow-up treatment.^[15]

Polythelia is linked with abnormalities of the urinary tract. Such abnormalities include supernumerary kidneys, failure of renal formation, and carcinoma of the kidney.^[16-18] The association of polythelia and renal anomalies is not ironclad but is supported by some studies. A study from Israel^[19] reported 40% of children with polythelia had obstructive renal anomalies or duplications of the excretory system. The presence of extra nipples in children should heighten the clinician's suspicion of possible renal anomalies. Nonrenal anomalies can involve the cardiovascular, central nervous, and gastrointestinal systems, in addition to chromosomal abnormalities and genetic syndromes.^[20] Cardiovascular problems associated with polythelia include congenital heart anomalies, high blood pressure, and conduction or rhythm disturbances.^[18] An association with testicular tumors has been cited.^[21] Polythelia associated with familial alcoholism has also been suggested.^[22]

Commonly, polymastia and polythelia occur sporadically, but familial cases are reported.^[23,24] In families, supernumerary breast tissue can be seen in siblings or across generations. Toumbis-Ioannou and Cohen^[24] describe a woman with left-sided polythelia and an ectopic right kidney. Her older sister had left-sided polythelia, and her brother had a complete supernumerary breast on his left side. Klinkerfuss^[25] reported on polymastia in four generations of a family.

Most cases of supernumerary breasts and nipples occur within the milk line running from the axilla to the groin. However,

there are rare, unusual cases in which they occur elsewhere. Such breasts have been referred to as "mammas erraticas."^[3,8] Unusual locations include the buttock, back of neck, face, flank, upper arm, hip, shoulders, and midline of the back and chest.^[8,26] A highly unusual case^[3] reported in 1980 involved a well-formed mass resembling a female breast on the back thigh in a 74-year-old man (Fig 3). A quote from that article: "He stated that he had this 'fatty tumor' almost all of his life and that it never caused a problem (ie, secreted)."^[3] The patient refused removal of the breast. Hollywood has not overlooked breast anomalies. The villain in the James Bond movie *The Man with the Golden Gun* had a third nipple. A mutant in the Arnold Schwarzenegger movie *Total Recall* had a third breast mid-sternum.

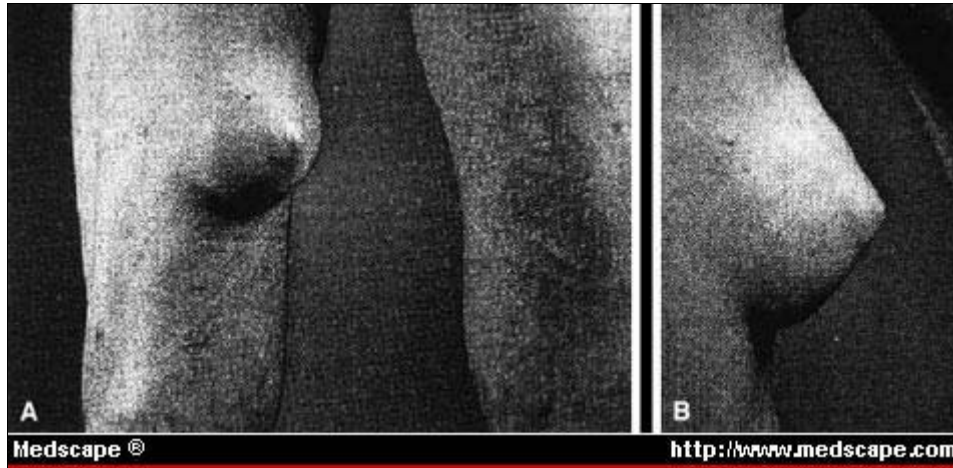


Figure 3. Supernumerary breast on posterior thigh of 74-year-old man. (Reprinted with permission from Camisa.^[3])

Individual cases of polymastia and polythelia are exceptional. The highest number of supernumerary breasts, reported by Neugebauer in 1886,^[8(p72)] was eight in addition to the two normal breasts. A report in 1675 described the presence of five nipples on the left breast and two on the right.^[8(pp 96,97)] There are numerous reports of infants nursed from supernumerary breasts.^[8] An often cited case^[8] from 1827 refers to Therese Ventre of Marseilles, France. Her mother had a supernumerary breast beneath her normally positioned right breast. Ventre had a supernumerary breast on the side of her left thigh. This breast enlarged during puberty, and when she became pregnant, it produced milk. It was offered to her infant who took it willingly. She apparently nursed five children during her life from all three of her breasts. Although the woodcut showing children nursing from both her right breast and thigh breast did not accompany the original papers describing this woman's case, it has often been used in reference to her (Fig 4).^[27] In a disputed case,^[8] a woman who had breasts on her shoulders was said to have drawn them forward beneath her arms to let her children nurse. Other cases^[8(p73)] include nursing from breasts located in the groin and nursing from a third breast located in the midline of the chest.

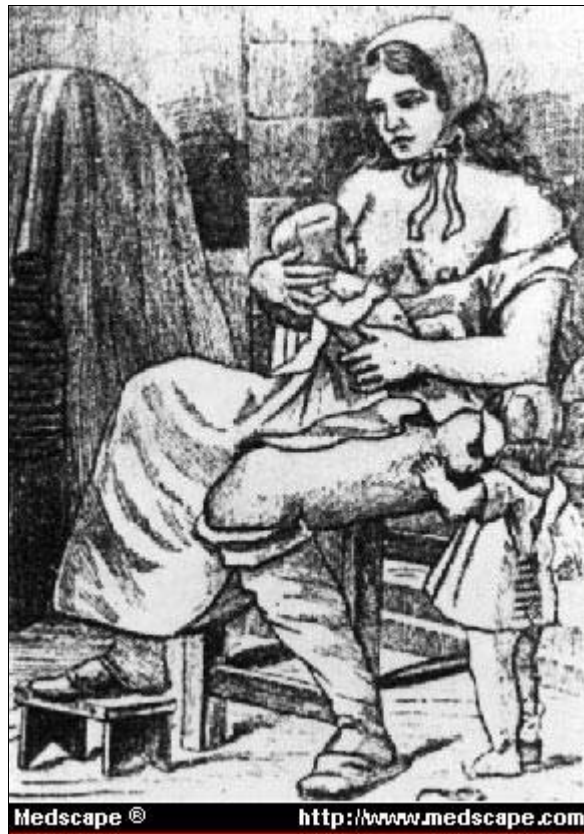

Figure 4. Old woodcut representing polymastia.

Conclusions

Supernumerary breast tissue has been recorded over the centuries. Its alliance with increased fertility, as evidenced in the ancient worship of Artemis and commonly believed in the 1800s, has been proven false. Cases of breast feeding from fully formed ectopic breasts fall into the realm of medical history and curiosities. Today it is clearly evident that the presence of supernumerary breast tissue is linked with other organ system anomalies -- in particular those of the urinary tract. This association can be explained by the parallel embryologic development of mammary parts and the genitourinary system. Other organ system anomalies and even malignancies are linked with supernumerary breast tissue. Studies concerning this link are often small series or case reports. Further research is needed to more deeply understand this phenomenon and its associations and to refine appropriate clinical workup in such cases.

References

1. Kajawa Y: The proportions of supernumerary nipples in the Finnish population. *Duodecim* 1915; 31:143-170
2. Velanovich V: Ectopic breast tissue, supernumerary breasts, and supernumerary nipples. *South Med J* 1995; 88:903-906
3. Camisa C: Accessory breast on the posterior thigh of a man. *J Am Acad Dermatol* 1980; 3:467-469
4. Mansel RE, Dixon JM: Congenital problems and aberrations of normal breast development and involution. *BMJ* 1994; 309:797-800
5. Decholnoky T: Accessory breast tissue in the axilla. *NY State Med J* 1951; 51:2245-2248
6. Bland KI, Romrell LJ: Congenital and acquired disturbances of breast development and growth. *The Breast: Comprehensive Management of Benign and Malignant Diseases*. Bland KI, Copeland EM III (eds). Philadelphia, WB Saunders, 2nd Ed, 1998, pp 214-232
7. Monaghan P: *The Book of Goddesses and Heroines*. St. Paul, Minn, Llewellyn Publications, 1990,
8. Deaver JB, McFarland J: *The Breast: Its Anomalies, Its Diseases, and Their Treatment*. Philadelphia, P Blakiston's Son and Co, 1917, pp 45-101
9. Darwin C: *The Descent of Man and Selection in Relation to Sex*. New York, Appleton and Co, 1892, pp 36-37
10. Brightmore TGJ: Cystic lesion of a dorsal supernumerary breast in a male. *Proc R Soc Med* 1971; 64:662-663
11. O'Hara MF, Page DL: Adenomas of the breast and ectopic breast under lactational influences. *Hum Pathol* 1985; 16:707-712
12. Hassim AM: Bilateral fibroadenoma in supernumerary breasts of the vulva. *J Obstet Gynaecol Br Commonwealth*

1969; 76:275-277

13. Vargas J, Nevado M, Rodriguez-Peralto JL, et al: Fine needle aspiration diagnosis of carcinoma arising in an ectopic breast. a case report. *Acta Cytol* 1995; 39:941-944
14. Bailey CL, Sankey HZ, Donovan JT, et al: Primary breast cancer of the vulva. *Gynecol Oncol* 1993; 50:379-383
15. Newman M: Supernumerary nipples. *Am Fam Phys* 1988; 38:183-188
16. Méhes K, Szüle E, Törzsök F, et al: Supernumerary nipples and urologic malignancies. *Cancer Genet Cytogenet* 1987; 24:185-188
17. Goedert JJ, McKeen EA, Fraumeni J: Polymastia and renal adenocarcinoma. *Ann Intern Med* 1981; 95:182-184
18. Pellegrini JR, Wagner RF: Polythelia and associated conditions. *Am Fam Phys* 1983; 28:129-132
19. Varsano IB, Jaber L, Garty BZ, et al: Urinary tract abnormalities in children with supernumerary nipples. *Pediatrics* 1984; 73:103-105
20. Cohen PR, Kurzrock R: Miscellaneous genodermatoses: Beckwith-Wiedemann syndrome, Birt-Hogg-Dube syndrome, familial atypical multiple mole melanoma syndrome, hereditary tylosis, incontinentia pigmenti, and supernumerary nipples. *Dermatol Clin* 1995; 13:211-229
21. Goedert JJ, McKeen EA, Javadpour N, et al: Polythelia and testicular cancer. *Ann Intern Med* 1984; 101:646-647
22. König P, Haller R, Dunser H: Polythelie bei alkoholkranken (vorläufige mitteilung). *Wien Med Wochenschr* 1985; 135:443- 446
23. Weinberg SK, Motulsky AG: Aberrant axillary breast tissue: a report of a family with six affected women in two generations. *Clin Genet* 1976; 10:325-328
24. Toubis-Ioannou E, Cohen PR: Familial polythelia. *J Am Acad Dermatol* 1994; 30:667-668
25. Klinkerfuss GH: Four generations of polymastia. *JAMA* 1924; 82:1247-1248
26. Hanson E, Segóvia J: Dorsal supernumerary breast. case report. *Plast Reconstr Surg* 1978; 61:441-445
27. Harper R: Supernumerary nipples and neurosis. *Lancet* 1948; 1:901

Reprint Address

Reprint requests to Norman A. Grossl, MD, Department of Pathology Grady Memorial Hospital, 80 Butler St, Atlanta, GA 30335.

South Med J. 2000;93(1) © 2000 Lippincott Williams & Wilkins